

# AMERICAN ACADEMY OF PEDIATRICS

## CLINICAL REPORT

Guidance for the Clinician in Rendering Pediatric Care

John Persing, MD; Hector James, MD; Jack Swanson, MD; John Kattwinkel, MD; Committee on Practice and Ambulatory Medicine; Section on Plastic Surgery; and Section on Neurological Surgery

### Prevention and Management of Positional Skull Deformities in Infants

**ABSTRACT.** Cranial asymmetry may be present at birth or may develop during the first few months of life. Over the past several years, pediatricians have seen an increase in the number of children with cranial asymmetry, particularly unilateral flattening of the occiput. This increase likely is attributable to parents following the American Academy of Pediatrics "Back to Sleep" positioning recommendations aimed at decreasing the risk of sudden infant death syndrome. Although associated with some risk of deformational plagiocephaly, healthy young infants should be placed down for sleep on their backs. This practice has been associated with a dramatic decrease in the incidence of sudden infant death syndrome. Pediatricians need to be able to properly diagnose skull deformities, educate parents on methods to proactively decrease the likelihood of the development of occipital flattening, initiate appropriate management, and make referrals when necessary. This report provides guidelines for the prevention, diagnosis, and management of positional skull deformity in an otherwise normal infant without evidence of associated anomalies, syndromes, or spinal disease.

---

ABBREVIATIONS. AAP, American Academy of Pediatrics; SIDS, sudden infant death syndrome.

---

Flattening of the occiput may be caused by mechanical factors acting on the head in utero or during early infancy. This common condition has been referred to by many names, such as benign positional molding, posterior plagiocephaly, occipital plagiocephaly, plagiocephaly without synostosis, and deformational plagiocephaly. Ancient civilizations intentionally deformed skulls by selective positioning and external plates. The term plagiocephaly is a Greek derivative meaning "oblique head."

Most skull deformities present at birth are the result of in utero or intrapartum molding. Associated conditions involve uterine constraint, especially in cases of multiple birth infants, and birth injury associated with forceps or vacuum-assisted delivery.<sup>1,2</sup> Infants born prematurely also have a greater incidence of skull deformity attributable to molding after

birth. Most of these deformities improve spontaneously during the first few months of life if the infant does not rest his or her head on the flattened area of the skull. If the infant continues to rest his or her head on the flattened side of the occiput, an initially occipital plagiocephalic deformity may be perpetuated or worsened by gravitational forces.<sup>3</sup> Occipital flattening and atypical shape also may be caused by craniosynostosis, particularly lambdoid craniosynostosis.

If the skull deformity develops postnatally, an initially typical, rounded skull shape may become flattened occipitally as a result of static supine positioning. Associated torticollis or "wryneck" may occur as a consequence of hemorrhage (within the sternocleidomastoid muscle) and/or subsequent scarring within the sternocleidomastoid muscle, or muscle shortening caused by persistent, unidirectional positioning and limited neck motion.

Incidence of deformational plagiocephaly has been estimated to be as low as 1 in 300 live births to as high as 48% of typical healthy infants younger than 1 year, depending on the sensitivity of the criteria used to make the diagnosis.<sup>1</sup> In contrast, the incidence of isolated lambdoid craniosynostosis is quite rare, estimated to be approximately 3 in 100 000 births (0.003%).<sup>4</sup>

Beginning in 1992, there has been a significant increase in the diagnosis of deformational plagiocephaly, with 1 medical center observing more than a sixfold increase from the years 1992–1994.<sup>1,5,6</sup> The increasing incidence of deformational plagiocephaly is likely related to the recommendation of the American Academy of Pediatrics (AAP) and others that infants be placed on their backs for sleep.<sup>7</sup> Prone, and to a lesser extent, side sleeping during early infancy has been linked with sudden infant death syndrome (SIDS). Since the AAP "Back to Sleep" campaign was launched in 1992, prone sleeping has decreased markedly and national SIDS rates have decreased more than 40%.<sup>8</sup> Despite the increase in deformational plagiocephaly, it is clear that the supine sleep position recommendation should be followed for the vast majority of infants.

It is important to note the natural history of deformational plagiocephaly, which likely has existed for centuries, although at a lower rate than at present.

---

The guidance in this report does not indicate an exclusive course of treatment or serve as a standard of medical care. Variations, taking into account individual circumstances, may be appropriate.

PEDIATRICS (ISSN 0031 4005). Copyright © 2003 by the American Academy of Pediatrics.

Most infants with deformational plagiocephaly have gone unrecognized or have been treated expectantly. Significant deformity may persist in some individuals into adolescence. Minor craniofacial asymmetry can be detected in a significant number of adults; however, there are few current cases of deformational plagiocephaly serious enough to be acknowledged by patients.<sup>4</sup>

### PREVENTION

The pediatrician or other primary care clinician should educate parents as well as other health care professionals, such as those in newborn care units, on methods to decrease the risk of development of deformational plagiocephaly. A certain amount of prone positioning, or "tummy time," while the infant is awake and being observed is recommended to help prevent the development of flat spots on the occiput and to facilitate development of upper shoulder girdle strength necessary for timely attainment of certain motor milestones.<sup>8</sup> Beginning at birth, most deformational plagiocephaly also can be prevented by nightly alternating the supine head position (ie, left and right occiputs) during sleep and periodically changing the orientation of the infant to outside activity such as is likely to occur at the door of the room.

### DIAGNOSIS

Diagnosis of cranial asymmetry in general, and deformational plagiocephaly in particular, can be determined on examination at birth and at each health supervision visit up to 1 year of age. It is important for the pediatrician or other examiner to look down at the top of the head, view the position of the ears, and note the position of the cheekbones (zygomas). By doing this, the typical deformational plagiocephaly, which forms a parallelogram, will be observed. In addition to the usually unilateral flattening of the occipital area, there may be ipsilateral frontal (forehead) and parietal bossing, cheekbone prominence, and anterior ear displacement ipsilateral to the flattened occiput (Fig 1).

Examination of the face also may lead to detection of abnormalities, such as head tilt and contralateral facial flattening. An assessment of neck movements also should be made to confirm or rule out the presence of torticollis. Infants with torticollis have some limitation of active rotation of their heads away from the flattened side of the occiput. The rotating chair or stool test is a procedure to assist in the diagnosis of torticollis associated with deformational plagiocephaly. The examiner sits on a rotating chair or stool and holds the infant facing the parent. Although the parent attempts to keep the infant interested in maintaining eye contact, the examiner rotates with the infant on the chair or stool and observes the infant's head movements. The difference between movement toward and away from the flattened side is helpful in making the diagnosis of torticollis associated with deformational plagiocephaly.

The diagnosis of deformational plagiocephaly in infancy is made primarily on the basis of history and is confirmed by the physical examination. If the pa-

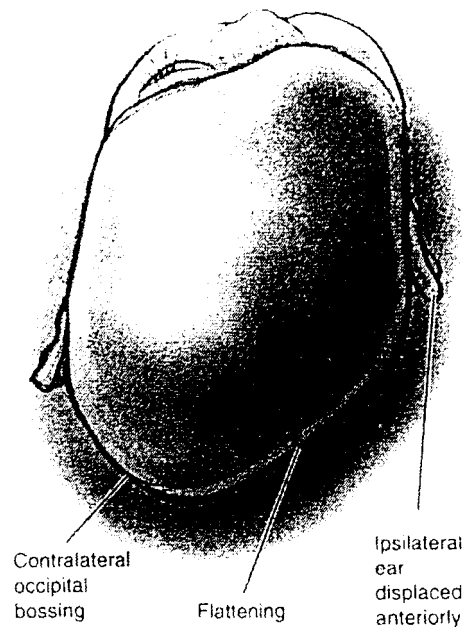


Fig 1. Positional molding. Adapted with permission from Lin KY, Ogle RC, Jane JA, eds. *Craniofacial Surgery: Science and Surgical Technique*. Philadelphia, PA: WB Saunders Company; 2002.

tient had a typical rounded head at birth and after a few weeks or months has parallelogram deformity and occipital flattening, the diagnosis of deformational plagiocephaly should be made. On the other hand, if the head has occipital flattening at the time of birth, the diagnosis of lambdoid craniosynostosis should be considered. Like deformational plagiocephaly, lambdoid craniosynostosis produces a flat occiput on one side of the head and prominence on the contralateral side, and deformation may become more severe with time. The degree of frontal asymmetry is generally less but similar in pattern to deformational plagiocephaly, which is frontal prominence ipsilateral to occipital flattening. The pattern of other associated features, however, almost always differs from deformational plagiocephaly. Specifically, the ear ipsilateral to the flattened occiput is typically posterior and displaced inferiorly when compared with the contralateral ear. The posterior basal skull also is tilted with the mastoid process in this region unusually prominent. Facial deformity typically is minimal, if present at all. However, in very rare instances, the deformities seen with lambdoid craniosynostosis may be similar to those of deformational plagiocephaly.<sup>9</sup>

### SKULL RADIOGRAPHS AND CRANIAL COMPUTED TOMOGRAPHY SCANS

Because the diagnosis of deformational plagiocephaly is made on the basis of history and findings on physical examination, imaging studies are unnecessary in most situations. Additionally, their interpretations, if obtained, may be misleading to clinicians. In cases of atypical skull pattern or moderate or severe skull deformity, skull radiographs may be used to explore the possibility of a diagnosis other than deformational plagiocephaly, such as cranio-

synostosis. A computed tomography scan evaluation may be further helpful for cases in which doubt remains after clinical and radiographic examinations. Radiographs will show obliteration of the lambdoid suture, and computed tomography scans will demonstrate a premature bridging of bone across the lambdoid suture and a constricted posterior cranial fossa ipsilateral to the fused lambdoid suture in cases of lambdoid craniosynostosis.

### MANAGEMENT

Management of deformational plagiocephaly involves preventive counseling of parents, mechanical adjustments, and exercises. Parental compliance with the management plan is pivotal in lessening the likelihood and severity of skull deformity. Skull molding helmets are an option for patients with severe deformity or skull shape that is refractory to therapeutic physical adjustments and position changes. Surgery is rarely necessary but may be indicated in severe refractory cases of deformational plagiocephaly or in patients with craniosynostosis.

#### Preventive Counseling

To prevent the deformity, parents should be counseled during the newborn period (by 2 to 4 weeks of age) when the skull is maximally deformable. Parents should be instructed to lay the infant down to sleep in the supine position, alternating positions (ie, left and right occiputs). When awake and being observed, the infant should spend time in the prone position. The infant should spend minimal time in car seats (when not a passenger in a vehicle) or other seating that maintains supine positioning. Once deformational plagiocephaly has developed, these same preventive strategies may be used to minimize progression. Additionally, it is important to monitor head shape closely until there is confidence that improvement will continue, usually when the infant is old enough to sit, crawl, and spend less time on his or her back, and until any associated torticollis is completely corrected.

#### Mechanical Adjustments and Exercises

Once deformational plagiocephaly is diagnosed, the parent should be made aware of the condition and the mechanical adjustments that can be instituted. In general, most infants improve if the appropriate measures are conducted for a 2- to 3-month period. These include positioning the infant so that the rounded side of the head is placed dependent against the mattress. Additionally, the position of the crib in the room may be changed to require the child to look away from the flattened side to see the parents and others in his or her room. The pediatrician should continue to encourage supervised "tummy time" on firm surfaces when the infant is awake and being observed. Torticollis perpetuates the position of the head on the flattened side and can add to a greater facial deformity. Therefore, if torticollis is present, neck motion exercises should be taught to the parents as part of management. Neck exercises should be done with each diaper change. There are 3 repetitions per exercise, and it is estimated to take

approximately 2 additional minutes per diaper change. One hand is placed on the child's upper chest, and the other hand rotates the child's head gently so that the chin touches the shoulder. This is held for approximately 10 seconds. The head is then rotated toward the opposite side and held for the same count. This will stretch out the sternocleidomastoid. Next, the head is tilted so that the infant's ear touches his or her shoulder. Again, the position is held for a count of 10 and repeated for the opposite side. This second exercise stretches the trapezius muscle. Additionally, the parents may be taught the rotating chair or stool technique to enhance neck motion in the infant.

#### Referral

If there is progression or lack of improvement of the skull deformity after a trial of mechanical adjustments, then referral to a pediatric neurosurgeon, a general neurosurgeon with expertise in pediatrics, or a craniofacial surgeon or craniofacial anomalies team should be considered. The purpose of this referral is to obtain the expertise of the pediatric surgical specialist on whether the correct diagnosis has been made and to direct the subsequent management, which may include molding helmets or surgery. Additionally, referral to a physical therapist may be considered if torticollis does not improve with neck stretching exercises within 2 to 3 months.

#### Skull-Molding Helmets

Several ancient civilizations have used head-molding devices in infants to reshape a typically shaped skull into a different but desired skull form. Conversely, skull-molding helmets can be used to correct atypical skull shapes, and similar devices are now proposed for this purpose. However, results from 1 study suggest that repositioning infants may produce improvement in mild to moderate cases similar to that reported with external orthotic devices.<sup>3</sup> Another study has linked the use of helmets with an improvement over that achieved by repositioning alone.<sup>10</sup> The best response for helmets occurs in the age range of 4 to 12 months because of the greater malleability of the young infant skull bone and the normalizing effect of the rapid growth of the brain. There is less modification of the cranial configuration when used after 12 months of age. The use of helmets and other related devices seems to be beneficial primarily when there has been a lack of response to mechanical adjustments and exercises. In most situations, an improvement to repositioning and neck exercise is seen over a 2- to 3-month period if these measures are instituted as soon as the condition is recognized. Because use of skull-molding helmets incurs significant cost, further studies are needed to identify outcomes with and without them.

#### Surgery

Management of deformational skull deformities can include surgery. Surgery is almost always indicated for craniosynostosis, and it has been used in rare instances for deformational plagiocephaly with-

out synostosis when the deformities are severe and resistant to nonsurgical measures.

### Summary

In most cases, the diagnosis and successful management of deformational plagiocephaly can be assumed by the pediatrician or other primary health care clinician. This includes examination for and counseling regarding deformational plagiocephaly in the newborn period and at health supervision visits during infancy, as well as monitoring for improvement or progression.

Mechanical methods, if performed early in life, may be effective in preventing further skull deformity and may reverse existing deformity. Referral to a pediatric neurosurgeon, a general neurosurgeon with expertise in pediatrics, or a craniofacial surgeon should be considered if there is progression or lack of improvement following a trial of mechanical adjustments.

#### COMMITTEE ON PRACTICE AND AMBULATORY MEDICINE, 2002–2003

Kyle E. Yasuda, MD, Chairperson  
F. Lane France, MD  
Lawrence D. Hammer, MD  
Norman Harbaugh, Jr, MD  
Philip Itkin, MD  
P. John Jakubec, MD  
Robert D. Walker, MD

Jack Swanson, MD  
Immediate Past Chairperson

#### LIAISONS

Adrienne A. Bien  
Medical Group Management Association  
Todd Davis, MD  
Ambulatory Pediatric Association  
Winston Price, MD  
National Medical Association

#### STAFF

Junelle P. Speller

#### SECTION ON PLASTIC SURGERY, 2002–2003

Seth Thaller, MD, Chairperson  
Bruce Bauer, MD  
Michael L. Bentz, MD  
David Billmire, MD  
Fernando Burstein, MD  
Louis Morales, MD, Vice Chairperson

John A. Persing, MD  
Immediate Past Chairperson

#### STAFF

Kathleen Kuk Ozmeral

#### SECTION ON NEUROLOGICAL SURGERY, 2002–2003

Marion L. Walker, MD, Chairperson  
Robin Humphreys, MD  
Hector E. James, MD  
J. Gordon McComb, MD  
Joseph H. Piatt, Jr, MD  
Harold ReKate, MD

#### STAFF

Chelsea Kirk

John Kattwinkel, MD  
Chairperson, Task Force on SIDS

### REFERENCES

1. Kane AA, Mitchell LE, Craven KP, Marsh JL. Observations on a recent increase of plagiocephaly without synostosis. *Pediatrics*. 1996;97:877–885
2. Littlefield TR, Kelly KM, Pomatto JK, Beals SP. Multiple-birth infants at higher risk for development of deformational of deformational plagiocephaly. *Pediatrics*. 1999;103:565–569
3. Moss SD. Nonsurgical, nonorthotic treatment of occipital plagiocephaly. What is the natural history of the misshapen neonatal head? *J Neurosurg*. 1997;87:667–670
4. ReKate HL. Occipital plagiocephaly: a critical review of the literature. *J Neurosurg*. 1998;89:24–30
5. Turk AE, McCarthy JG, Thorne CH, et al. The “back to sleep campaign” and deformational plagiocephaly: is there cause for concern? *J Craniofac Surg*. 1996;7:12–18
6. Argenta LC, David LR, Wilson JA, Bell WO. An increase in infant cranial deformity with supine sleeping position. *J Craniofac Surg*. 1996;7:5–11
7. American Academy of Pediatrics, Task Force on Positioning and Sudden Infant Death Syndrome. Positioning and SIDS. *Pediatrics*. 1992;89:1120–1126
8. American Academy of Pediatrics, Task Force on Infant Sleep Position and Sudden Infant Death Syndrome. Changing concepts of sudden infant death syndrome: implications for infant sleeping environment and sleep position. *Pediatrics*. 2000;105:650–656
9. Mernard RM, David DJ. Unilateral lambdoidsynostosis: morphological characteristics. *J Craniofac Surg*. 1998;9:240–246
10. Mulliken JB, Vander Woude DL, Hansen M, LaBrie RA, Scott RM. *Plast Reconstr Surg*. 1999;103:371–380

---

*All clinical reports from the American Academy of Pediatrics automatically expire 5 years after publication unless reaffirmed, revised, or retired at or before that time.*